

J.-N. Rippke^{1,2}, C. Eberle¹, A. Ellermann¹, T. Fritz¹, C. Sobau¹, P. Balcarek¹, N. Mengis^{1,2}

1 ARCUS Sportklinik, Pforzheim, Germany

2 Center of Orthopedic and Trauma Surgery, Kantonsspital Aarau, Aarau, Switzerland

Kantonsspital Aarau



INTRODUCTION

Anterior cruciate ligament (ACL) reconstruction is a standard procedure in the active patient. However, the number of ACL re-ruptures also rises, with an increasing number of ACL reconstructions (ACLR). In ACL revision surgery faulty tunnel position and widening require a two-staged treatment with tunnel filling and secondary ACLR to secure a proper fixation of the transplant¹. The current gold standard for tunnel filling is autologous corticocancellous iliac crest graft harvesting². But, the iliac crest donor site is associated with a significant number of complications causing the quest for alternative tunnel filling materials³.

AIM

The aim of this study was to investigate if allogenic bone graft is non-inferior to autologous corticocancellous iliac crest graft in terms of radiological bone regeneration and tunnel filling. An additional benefit of the allogenic bone graft was the assumed possibility of reduced surgery time.

METHOD

The study was designed as a prospective, randomized trial, including 41 patients who required 2 staged ACL revision surgery. The patients were randomized in two groups. The first group (17 patients) was treated with iliac crest corticocancellous graft the second (24 patients) with allogenic femoral head graft. 3 months postoperatively tunnel filling was measured via CT scan in the axial planes by dividing the area of the bone graft by the area of the whole tunnel (Fig 1)⁴. Additionally, the Hounsfield units of the filled area were compared to a representative native cancellous bone area of the proximal tibia (Fig 2)⁴. The surgery time was assessed for both groups.

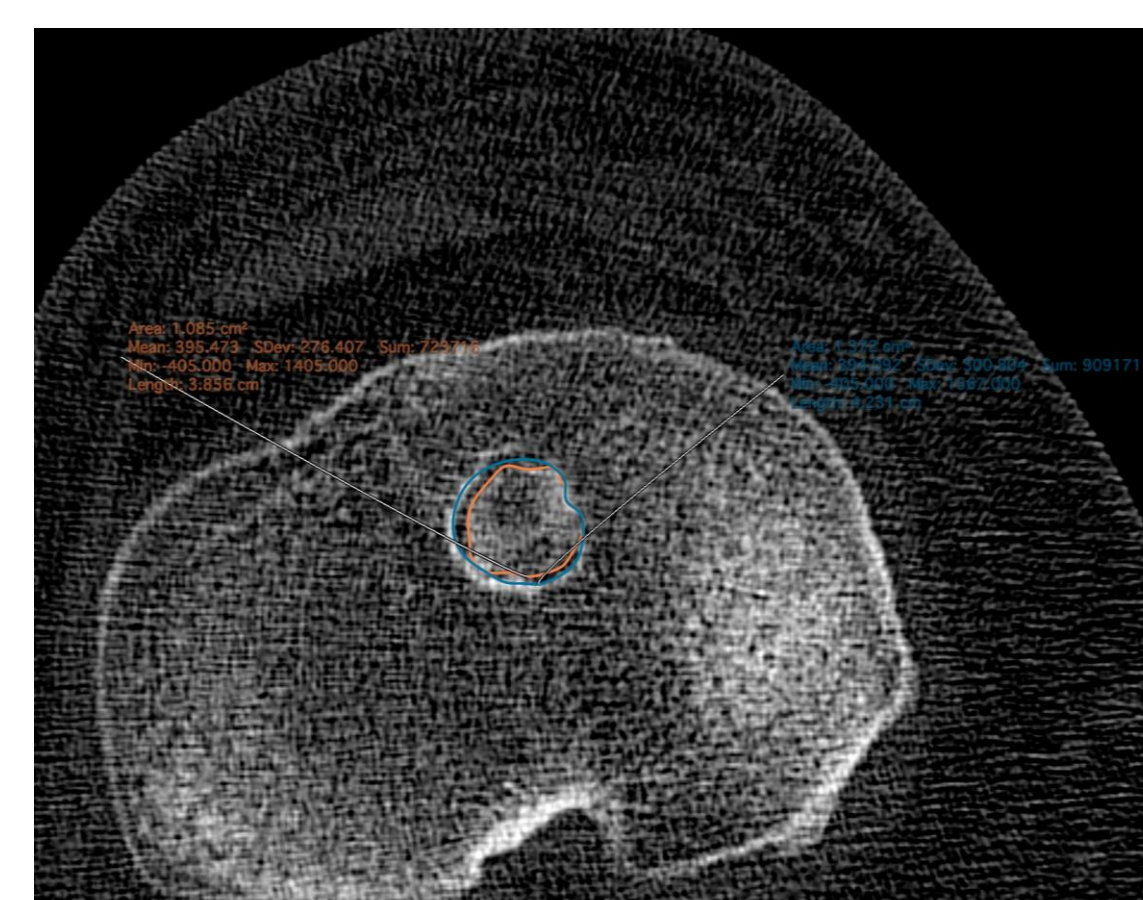


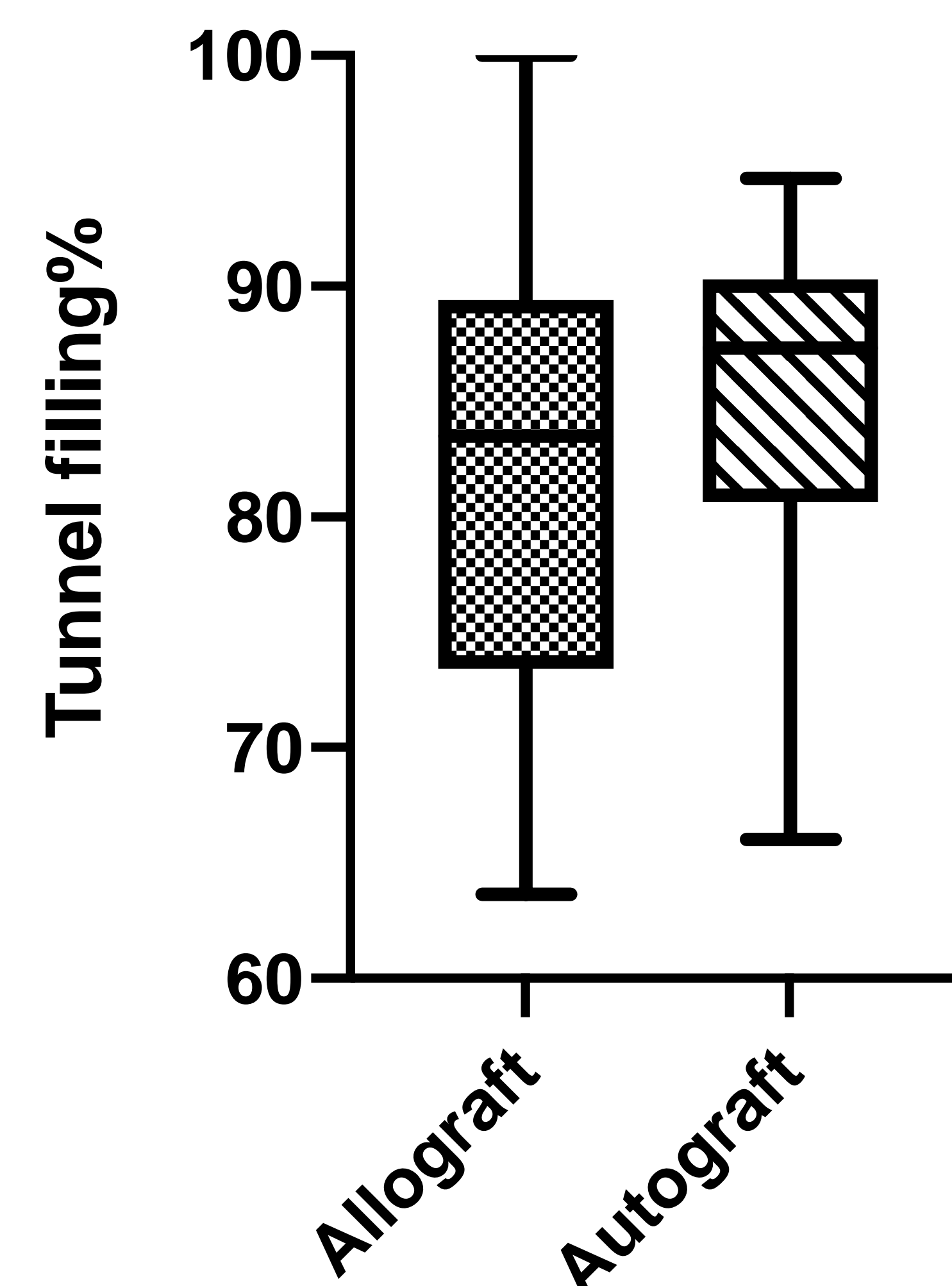
Fig 1

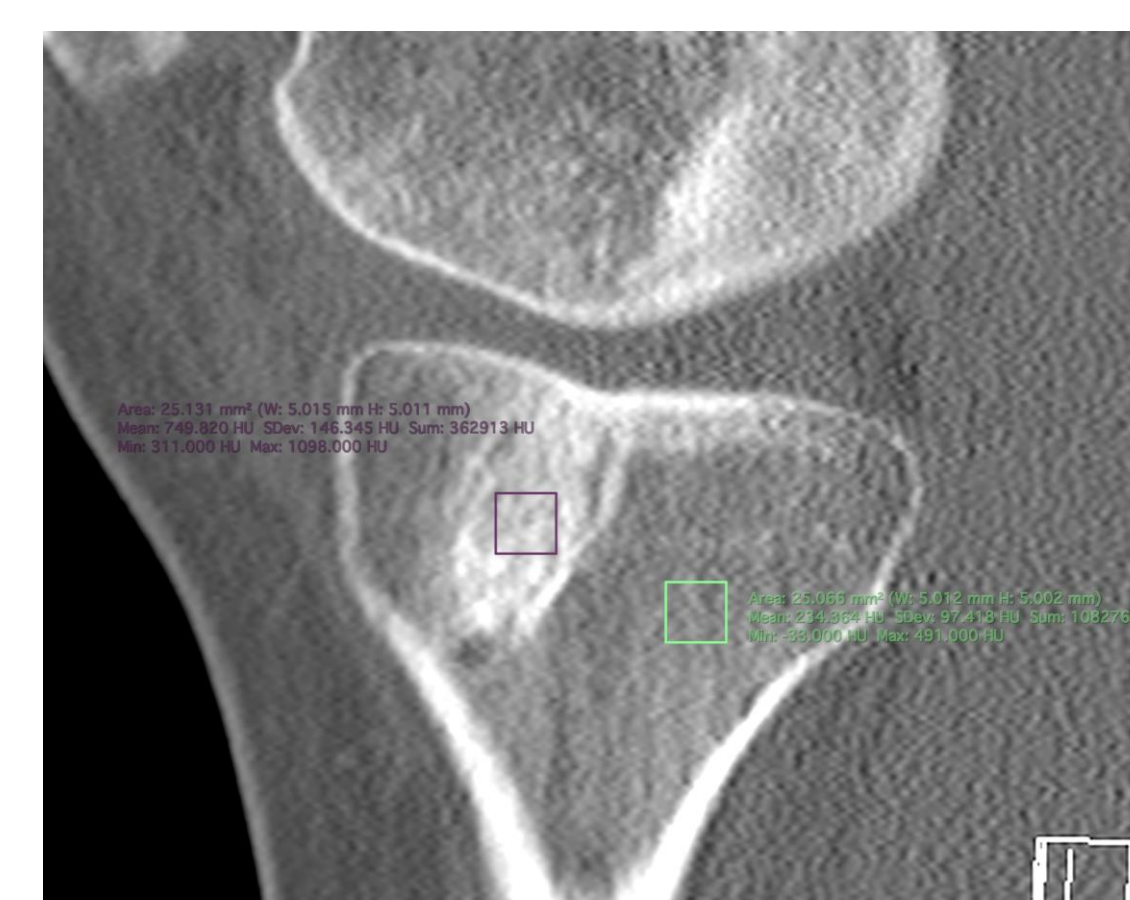

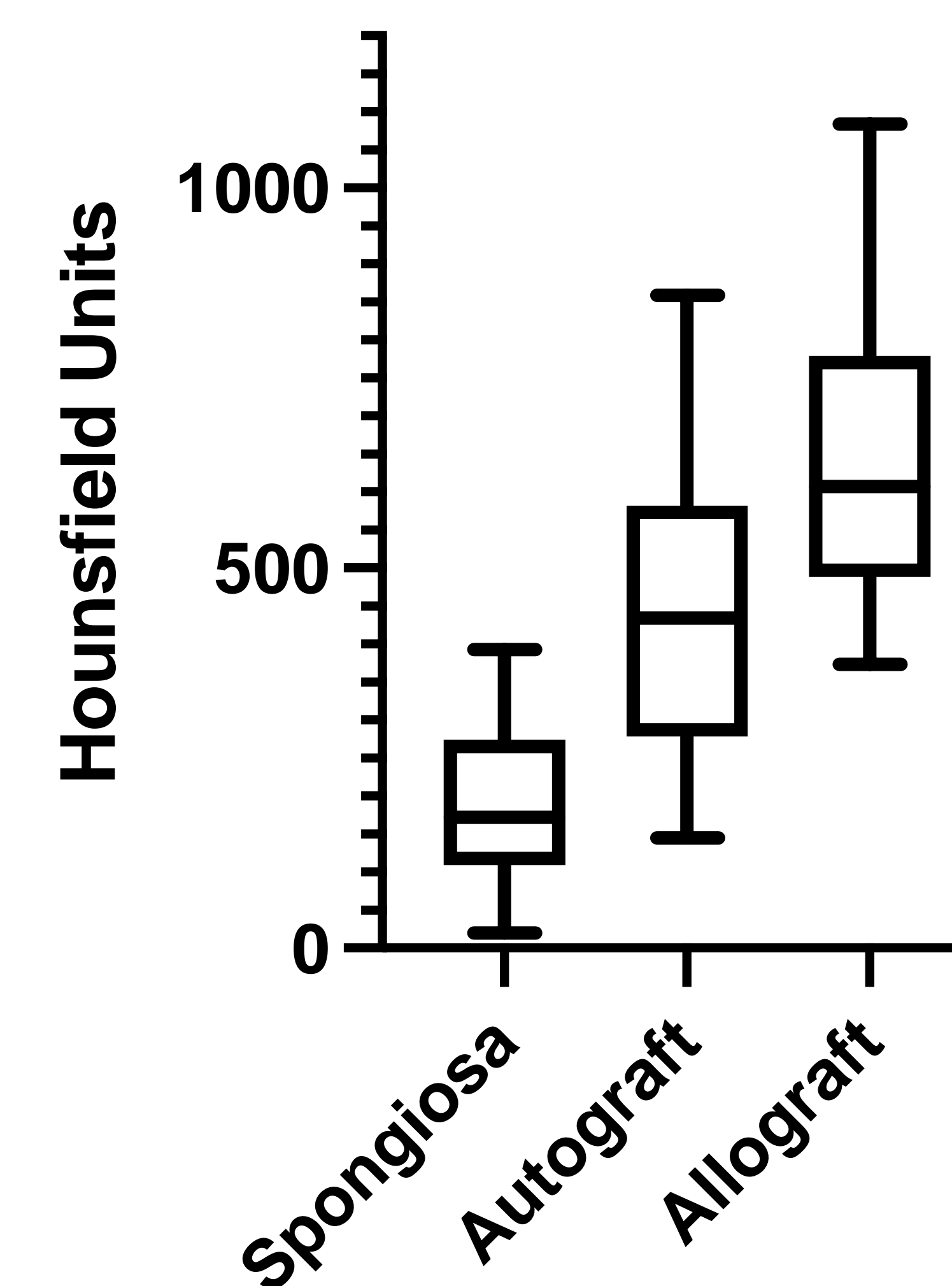
Fig 2

RESULTS

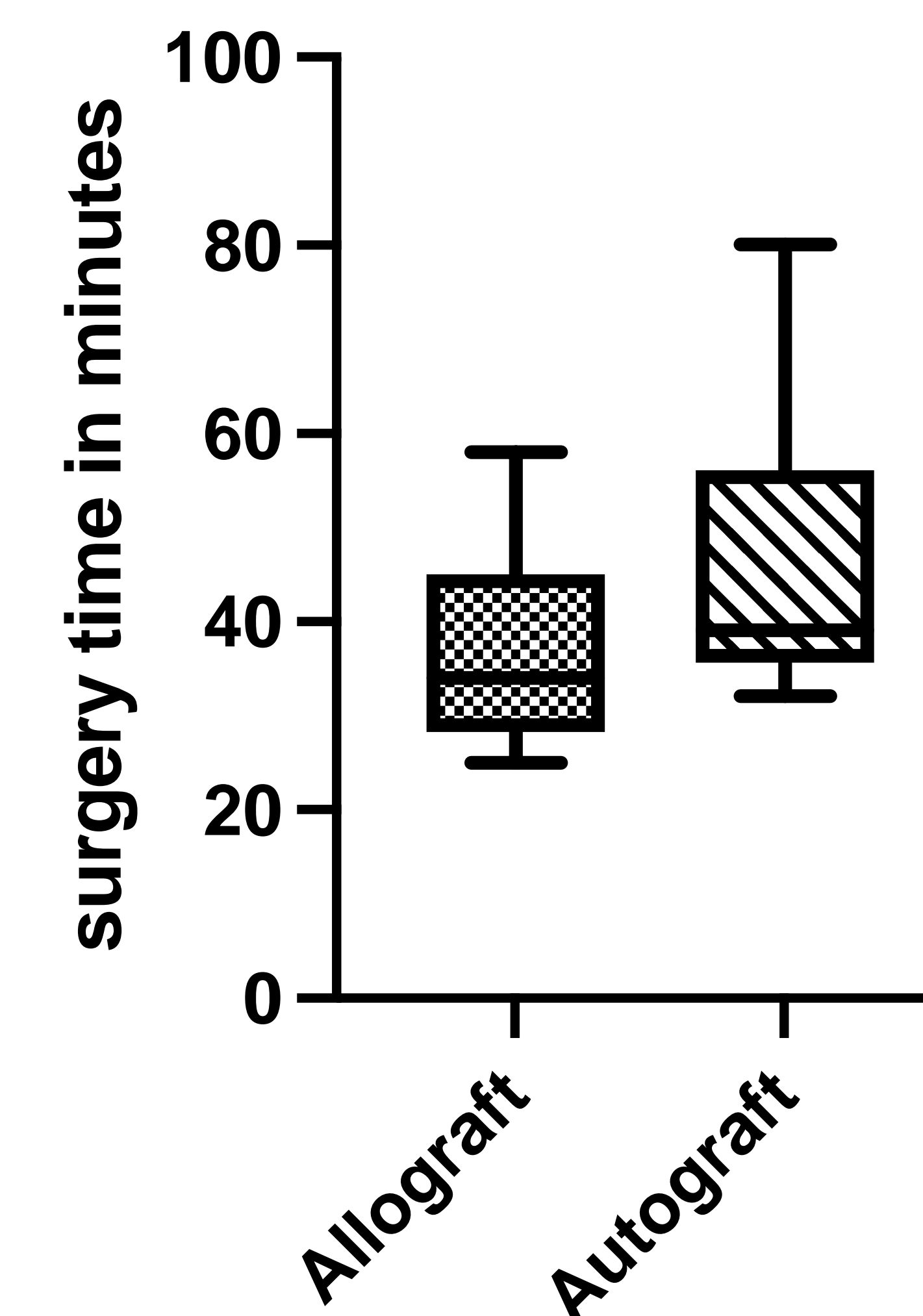
Bone regeneration showed comparable results in tunnel filling for autologous and allogenic grafts. The mean percentage of tunnel filling for allogenic bone graft was 82,61% to 84,94% (p=0,4415) for autologous corticocancellous graft.



Hounsfield units differed in both groups significantly (p<0,0001) compared to a representative native cancellous bone area of the proximal tibia. There was also a significant difference between the Hounsfield units with a mean of 630,5 for allograft and 431,7 for autograft (p=0,0015).



Surgery time was significantly shorter in the allograft group with a mean of 36 minutes compared to 46 minutes in the autograft group (p=0,0154).



CONCLUSIONS

Allogenic bone graft is non-inferior to the gold standard autologous corticocancellous bone graft in terms of the achieved percentage of tunnel filling. Both allograft and autograft showed Hounsfield units of cortical bone. This can be explained by the typical process of bone healing with callus formation and graft compaction. Autologous bone graft was closer to normal cancellous bone than the allogenic graft. In addition, surgery time can be significantly reduced by using allogenic bone graft. Further investigation of clinical outcomes comparing both grafting procedures are necessary.

REFERENCES

- 1 Achtenich A et al. High incidence of partially anatomic tunnel placement in primary single-bundle ACL reconstruction. *Knee Surg Sports Traumatol Arthrosc.* 2018 Feb;26(2):462-467. doi: 10.1007/s00167-017-4555-1. Epub 2017 Apr 24. PMID: 28439635.
- 2 Zantop T et al. Arthroscopic filling of malplaced and enlarged drill tunnels with iliac crest spongiosa in recurrent instability after anterior cruciate ligament reconstruction. *Oper Orthop Traumatol.* 2011 Oct;23(4):337-350. German. doi: 10.1007/s00064-011-0029-7. PMID: 22125816.
- 3 Arrington ED et al. Complications of iliac crest bone graft harvesting. *Clin Orthop Relat Res.* 1996 Aug;(329):300-9. doi: 10.1097/00003086-199608000-00037. PMID: 8769465.
- 4 von Recum J et al. Bone Incorporation of Silicate-Substituted Calcium Phosphate in 2-Stage Revision Anterior Cruciate Ligament Reconstruction: A Histologic and Radiographic Study. *Arthroscopy.* 2017 Apr;33(4):819-827. doi: 10.1016/j.arthro.2016.10.007. Epub 2016 Dec 30. PMID: 28043751.

ACKNOWLEDGEMENTS

We sincerely thank Mr. Prof. Dr. Wolf-Dieter Heller for the statistical analysis (Karlsruhe Institute of Technology, Karlsruhe, Germany)

CONTACT INFORMATION

Jules-N. Rippke (MD)
Arcus Sportklinik, Pforzheim, Germany
E-Mail: rippke@sportklinik.de